Journal of Clinical Periodontology

Official Journal of The European Federation of Periodontology

Founded by the British, Dutch, French, German, Scandinavian, and Swiss Societies of Periodontology

J Clin Periodontol 2009; 36: 705–711 doi: 10.1111/j.1600-051X.2009.01427.x

Journal of Clinical Periodontology

Immediate implants at fresh extraction sockets: bone healing in four different implant systems

Massimo de Sanctis[1], Fabio Vignoletti[2], Nicola Discepoli[2], Giovanni Zucchelli[3] and Mariano Sanz[4]

[1]Dipartimento di Scienze, Universitá degli stidi di Siena, Odontostomatologiche,Siena, Italy; [2]Universidad Complutense of Madrid, Periondotology, Madrid, Spain; [3]University of Bologna, Periondotology, Bologna, Italy; and [4]Faculty of Odontology, Universidad Complutense of Madrid, Madrid, Spain

de Sanctis M, Vignoletti F, Discepoli N, Zucchelli G, Sanz M. Immediate implants at fresh extraction sockets: bone healing in four different implant systems. J Clin Periodontol 2009; 36: 705–711. doi: 10.1111/j.1600-051X.2009.01427.x.

Abstract

Objectives: To describe the differences in bone healing, when placing four different implant systems in fresh extraction sockets.

Material and Methods: Eight beagle dogs received implants randomly installed into the distal socket of three P3 and four P4. Four-implant systems were evaluated. Each animal provided four test implant sites. All animals were sacrificed at 6 weeks after implant placement, providing specimens for histo-morphometric analysis of bone to implant contact (BIC), bone area, new bone formation, as well as histometric measurements of the ridge alterations.

Results: No statistically significant difference was observed among the four-implant systems. The mean BIC % ranged between 58.5% and 72.1%. Bone modelling of the buccal plate was marked and amounted approximately to 2.5 mm, independently of the system used.

Conclusion: This study failed to demonstrate differences in the healing pattern after 6 weeks when placing four different implant systems in fresh extraction sockets. In spite of achieving predictable osteointegration with the four implants studied, the occurrence of buccal bone resorption may limit the use of this surgical approach.

Key words: buccal crest; fresh extraction socket; implant surface; immediate implants; osteointegration

Accepted for publication 5 April 2009

In recent years, immediate implant placement after tooth extraction has become a common clinical therapeutic approach, alternative to a staged surgical protocol. The reduction in the number of surgeries needed and the advantage of a shorter time to rehabilitate function and aesthetic has provided an impetus to studies on this surgical approach.

Clinical studies have demonstrated that the survival rates for implants placed immediately, early, delayed or late seem to be similar in short-term follow-ups and range between 93% and 100%. Schropp et al. (2003) compared, in 46 patients, the bone healing and crestal bone changes following immediate *versus* delayed placement of titanium dental implants. In the immediate group, implants were placed 10 days after tooth extraction, while in the delayed group the placement of the implant was carried out 3 months after extraction. The survival rates at the end of the study were 91% in the immediate group and 96% in the delayed group. Covani et al. (2004) reported the results from a clinical study on 35 implants; 20 were placed immediately after tooth removal and 15 were placed between 4 and 6 weeks after the extraction. All implants were submerged, achieving primary flap closure. At re-entry both groups healed similarly, achieving a similar bone fill at the coronal portion of the implants (Covani et al. 2004, Ganeles & Wismeijer 2004). Ganeles & Wismeijer (2004) published a review of the available literature on this surgical protocol assessing its outcome under different loading protocols and different clinical indications (single tooth *versus* multiple teeth; bone quality, implants stability, etc.). Combined data for 1.046 implants yielded a survival rate of 98.2%. Most of the clinical studies have reported implant survival data well above 95%, thus demonstrating clinical outcomes similar to the delayed placement surgical protocol (Ganeles & Wismeijer 2004). Few studies have, however, studied the impact of this surgical approach on the bone crest in contact with the implant. Cornelini et al. (2005), in a prospective case series of 22 implants with a 12-month follow-up, reported a mean bone resorption of 0.5 mm at 12 months. Similarly, Covani et al. (2007) assessed 20 implants positioned in fresh extraction sockets resulting at 1 year in

Conflict of interest and source of funding statement

The authors declare that there are no conflict of interests in this study.
This study was partially sponsored by a research grant from Thommen Medicals.

the absence of peri-implant defects and with a vertical distance between the implant shoulder and bone crest ranging between 0 and 2 mm.

Experimental animal studies evaluating this surgical protocol have also demonstrated that implants show a similar degree of osseointegration compared with delayed inserted implants (Anneroth et al. 1985, Barzilay et al. 1991, 1996a, b, Karabuda et al. 1999). Parr and colleagues studied, in dogs, the bone healing around immediately placed titanium implants in both the mandible and the maxilla. At 5 months, the bone to implant contact (BIC) was 60.3% in the mandible and 46.3% in the maxilla. Barzilay et al. (1996a, b) compared the healing of immediate *versus* delayed implants in monkeys. The differences between both groups for BIC were not significant, with BIC values of 63.97% for the delayed implants and 56.82% for the immediately placed implants. Karabuda et al. (1999) have investigated the impact of different implant surfaces, by comparing the healing of hydroxyapatite-coated and titanium plasma-sprayed root-form implants placed immediately after tooth extraction in dogs. At 8 weeks, the mean BIC for HA-coated implants was 61.84%, while the corresponding value for the titanium plasma-sprayed implants was 51.35%.

Consequently, the purpose of this animal experiment was to determine whether the rate and extent of osseointegration is influenced when implants with different contacting surfaces and different designs are placed in an immediate implant placement surgical protocol. Furthermore, the secondary objective is to evaluate the influence that this may have on the modelling of the buccal plate.

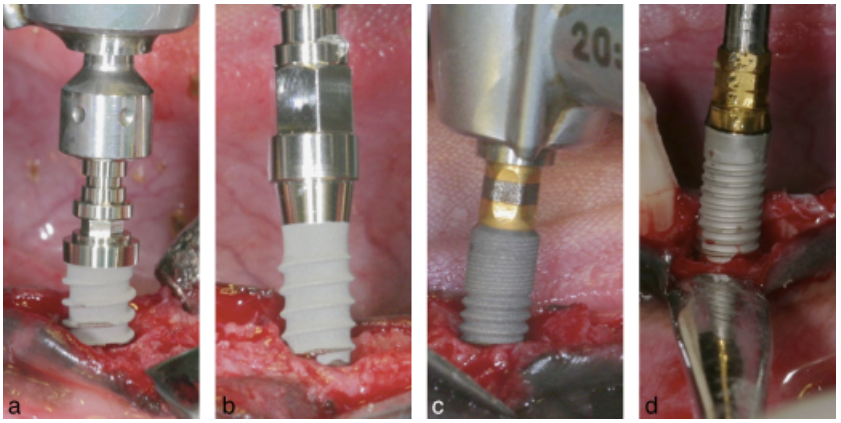

Fig. 1. Four implant systems were tested. (a) Thommen 3.5 SPI ELEMENT®. (b) Straumann 3.3 ITI Standard. (c) Astra 3.5 Micro Thread® OsseoSpeed®. (d) 3i Osseotite® Miniplant Certain straight.

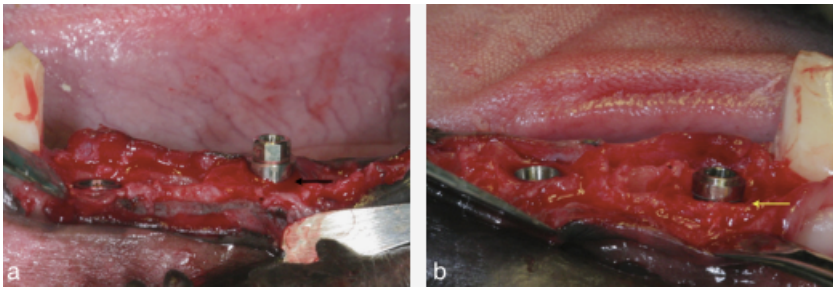

Fig. 2. Implant placement. (a) Note the supracrestal position of 1.8 mm polished collar of the Straumann implant (black arrow). (b) Note the supracrestal position of 1 mm polished collar of the Thommen implant (yellow arrow).

Material and Methods

This animal experiment was designed as a prospective, randomized controlled, evaluator-blinded study, carried out on adult beagle dogs with a weight ranging between 10 and 20 kg.

Study implants

Four-implant systems were evaluated: 3i (Biomet 3i, Palm Beach Gdns, Fl, USA, USA) Osseotite Certain straight Ø3.25 mm/l = 8.5, 11.0 mm; Astra (Astra Tech, Molndal, Sweden) MicroThread™-OsseoSpeed™ Ø3.5 mm/l = 9.0, 11 mm; Thommen (Thommen Medical AG, Waldenburg, Switzerland) SPI ELEMENT® Ø3.5 mm/l = 9.5 mm; Straumann (Straumann AG, Basel, Switzerland) ITI standard plus Ø3.3 mm/l = 8, 12 mm (Fig. 1a–d). All the implants used were commercially available. Thommen and Straumann implants presented a coronal polished collar of 1 and 1.8 mm, respectively.

This experimental animal study was carried out at the Experimental Surgical Centre of the Hospital ''Gomez-Ulla'' in Madrid, Spain, once the Regional Ethics Committee for Animal Research approved the study protocol.

Eight animals were selected that fulfilled the inclusion criteria. Each animal provided four-test implant sites. All animals were sacrificed 6 weeks after implant placement.

Surgical procedure

Animals were sedated and placed under general anaesthesia, using mechanical respiration throughout the entire surgery. Induction of sedation was achieved using propofol. General anaesthesia was achieved using isofluorane gas, delivered via an endotracheal tube, at concentrations of 0.7–1.5%, achieving a respiratory rate of approximately 12 breaths/min. The surgical protocol was described in detail by Vignoletti et al. (2009). Briefly, once the animals were anaesthetized, intrasulcular incisions were performed and full-thickness flaps were reflected in order to achieve access to the alveolar crest, with care to reduce bone exposition to the minimum. The third and fourth pre-molars were then extracted with minimal trauma aiming to preserve the walls of the sockets. The distal socket of each two-rooted pre-molar was chosen as the implant-recipient site. The mesial sockets were allowed to fill with blood and heal without intervention.

Implants were then randomized by means of scratch-off cards supplied for each study animal number. The four implants were randomly assigned to the distal sockets of P3 and P4, on each side of the mandible. The osteo-

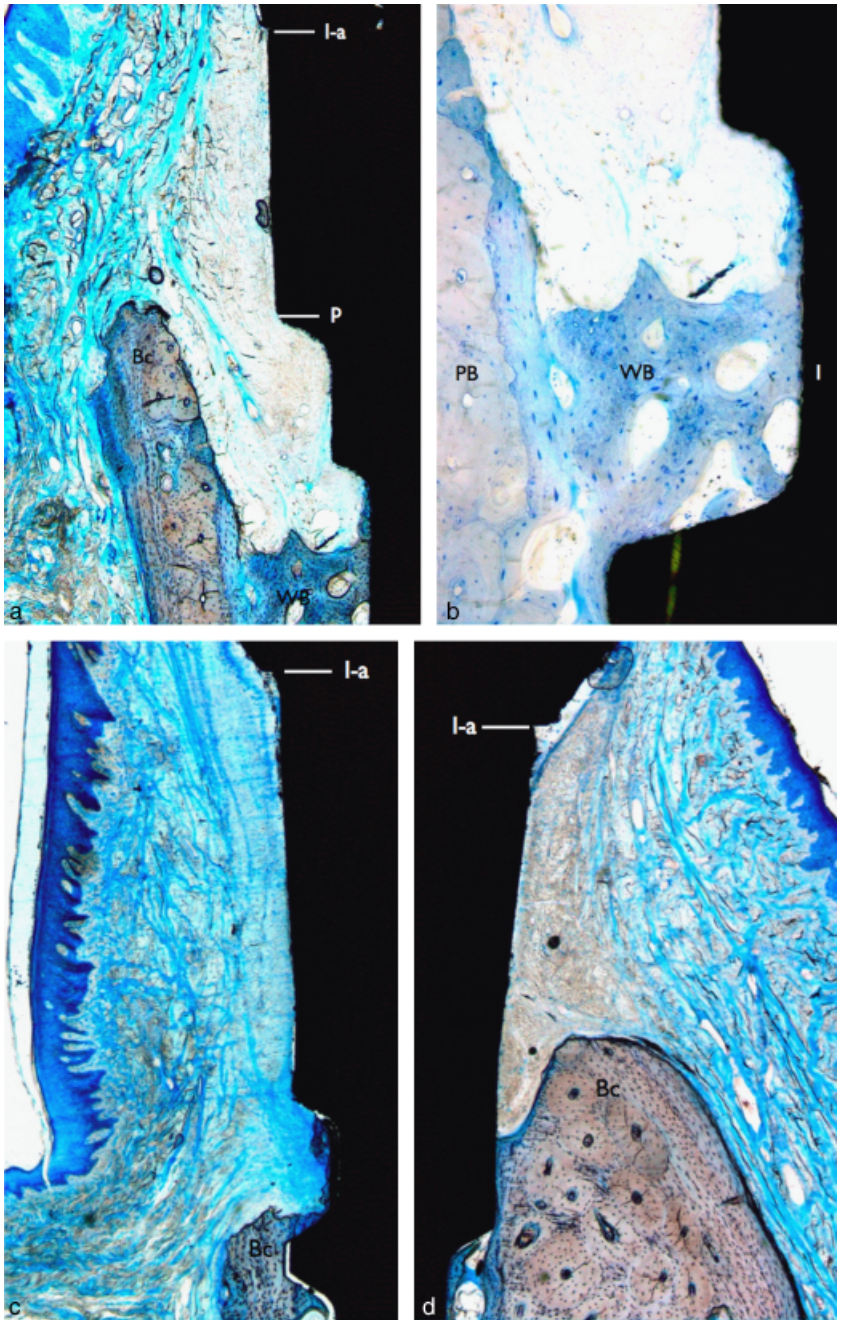

Fig. 3. Ground section representing implant and surrounding tissues. (a) The thin buccal bone crest (Bc) is levelled with the most apical level of the straight polished 1 mm collar (p) of the implant. Levai Laczko staining. Original magnification × 5. (b) Higher magnification af (a). Note the woven bone (dark stained areas, WB) in intimate contact with the implant surface (I) and continuous with the parent bone (PB). (Thommen SPI ELEMENT® implant). Levai Laczko staining. Original magnification × 10. (c, d). The bone crest (Bc) is observed at different levels apical of the implant shoulder (I). No residual vertical defect is present at the buccal crest (c). (3i Osseotite Certain straight implant). Levai Laczko staining. Original magnification × 5. I–a, implant–abutment interface.

tomies for inserting the different implant systems were performed according to the specific implant recommended surgical protocols. Hence, only original instruments specifically designed and recommended by the manufacturers were utilized. These osteotomies were drilled into the sockets to ensure that the implant seating platform was placed at the level of the marginal portion of the buccal plate for 3i and Astra implant, while Thommen and Straumann implants were inserted to a depth that placed the coronal margin of the rough surface at the level of the bone crest and the polished collars above the alveolar crest as suggested by the manufacturers (Fig. 2a and b). The depth of the osteotomy was based on the amount of available bone, with care not to engage the dental nerve or to cause a fenestration. Once the implants were inserted, healing abutments were secured and the flaps were repositioned and sutured with 4-0 vicryl resorbable sutures.

Post-surgical care

Plaque control was provided using a chlorhexidine solution sprayed on all mandibular tooth sites on a 3 days/week regimen. No effort was made to use any abrasive instrument for hygiene. All study implant sites were inspected before the hygienic treatment to evaluate the health of the peri-implant mucosa and document any signs of inflammation.

Biopsies

Animals were sacrificed with an overdose of sodium pentothal and perfused with a fixative solution (Karnovsky 1965) through the carotid arteries. The mandibles were freed from their attached tissues and cut into halves by means of a section between the central incisors. Each half mandible was placed into a sealable sample container. The sample containers were placed in a secure area at the proper temperature (5°C) from the time of collection until they were shipped for histological processing.

Histological processing and analysis

The obtained biopsies were processed for ground sectioning according to the methods described by (Donath & Breuner 1982). The blocks were cut in a bucco–lingual plane using a cutting–grinding unit (Exakt®, Apparatebau, Norderstedt, Germany). From each implant site, one central section was prepared and further reduced to a final thickness of about 20 μm by micro grinding and polishing using a micro-grinding unit (Exakt®). The sections were then stained using the Levai Laczko staining method.

Histometric analysis

The degree of osseointegration was evaluated by linear measurements of

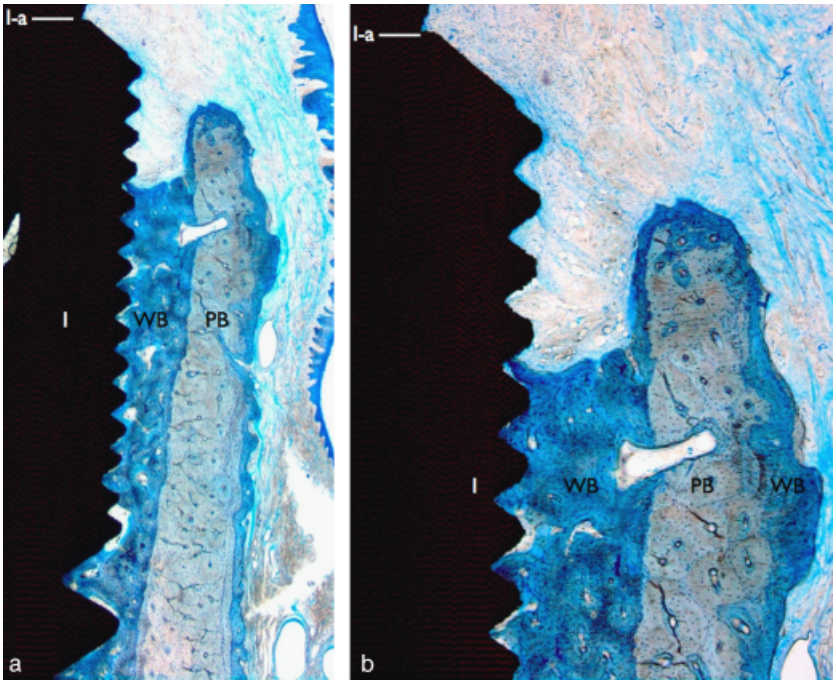

Fig. 4. Ground section representing implant and surrounding tissues. (a) The buccal bone crest is slightly apical of the implant–abutment interface. Levai Laczko staining. Original magnification × 2.5. (b) Higher magnification of (a). A residual vertical defect is present at the buccal crest. Note the woven bone (dark stained areas, WB) at the inner and at the outer part of the socket wall (Astra MicroThread®-OssesSpeed® implant). Levai Laczko staining. Original magnification × 5. I, implant surface. PB, parent bone. I–a, implant–abutment interface.

the percentage of ''bone to implant contact'' (BIC%) assessing the entire length of the implant surface in direct contact with mineralized bone from the coronal margin of the rough surface.

Ridge alterations

For assessing the relationship between the alveolar crest and the implant, the following landmarks were identified in each section and used for linear measurements:

I, implant shoulder;
Bc, marginal level of the bone crest;
B, marginal level of BIC.

The vertical distances between these landmarks were measured using a direction parallel to the long axis of the implants.

Histo-morphometric analysis

Newly formed bone area

Measurement of the percentage of newly formed bone that occupied the thread area of each implant.

Total bone area

Measurement of the total hard tissue component that occupied the thread area of each implant.

Statistical analysis

A one-way analysis of variance test was used to evaluate the differences among the implants used for each independent variable. A Bonferroni post hoc test was chosen to evaluate the differences among implant systems.

Results

Histological observations

The histological outcomes were similar for the four-implant systems studied. A marked bone loss was observed at the buccal aspect of the four-implant systems. The resorption of the buccal plate ranged between 0.5 and 5 mm. The mean position of the marginal bone crest was approximately 2.5 mm apical of the shoulder of the implant (Figs 3 and 4).

A gap of various dimensions frequently occurred between the socket walls and the implant surface at the time of installation. Buccally, this marginal gap healed 6 weeks after implant placement as a result of a combined bone resorption and new bone formation. Three different histological outcomes were identified: (i) no marginal gap was present and woven bone was observed up to the marginal bone crest, (ii) the most coronal BIC was located apical of the bone crest, resulting in a residual marginal gap of varying dimensions and (iii) occasionally newly formed bone was observed coronal to the bone crest margin (Figs 3–5).

Remnants of bundle bone were sometimes observed in the inner part of the socket wall. In such cases woven bone was observed continuous with the bundle bone. New bone formation was pronounced, both in intimate contact with the implant surface and with the mature lamellar bone from the bone bed. On some occasions, the newly formed bone was observed on the outer part of the bone crest. Extensive areas of bone remodelling were observed both in the parent bone and in the new bone (Fig. 6).

Histometric findings

BIC%

The results for the degree of osseointegration achieved by the different implant systems at 6 weeks are depicted in Table 1. BIC% presented a high variability. Values ranged from 39.84% to 78.63% for the 3i implants, from 35.78% to 76.58% for the Astra Tech implants, from 58.14% to 83.40% for the Straumann implants and from 50.13% to 86.88% for the Thommen implants. The mean BIC values were 58.5% (11.8), 60.2% (12.2), 72.1% (9.7) and 68.5% (11.5) for 3i, Astra Tech, Straumann and Thommen fixtures, respectively. Although there was a tendency towards higher BIC percentages around Straumann and Thommen fixtures, these differences were not statistically significant.

Ridge alterations

Histometric results demonstrated that at 6 weeks a marked bone remodelling of the crest occurred after implant placement. Measurements of vertical buccal bone resorption (I–Bc) were performed from the coronal edge of the rough surface, because the machined collars

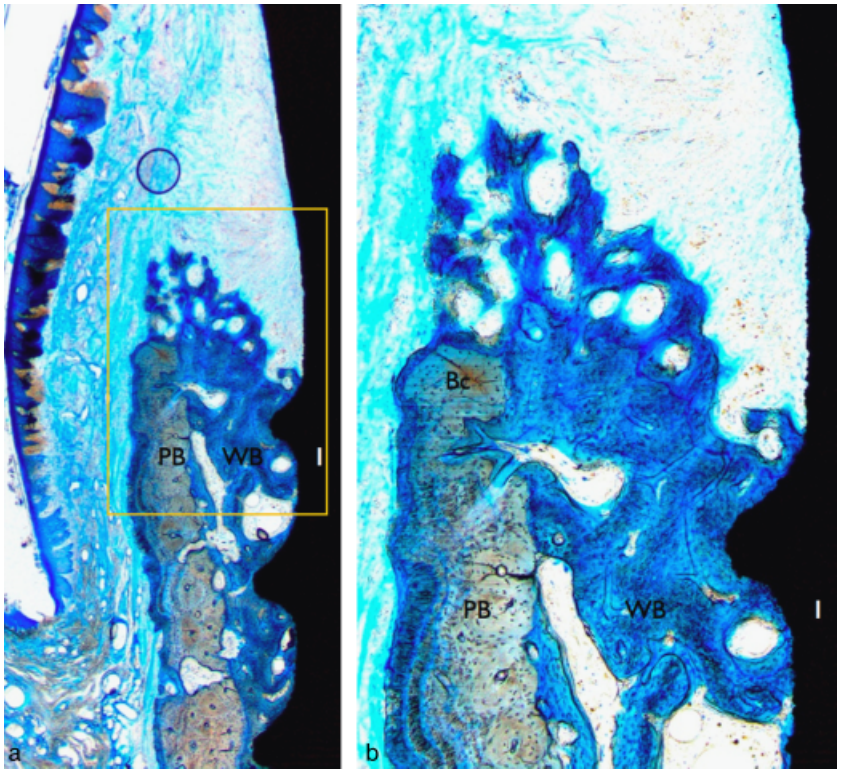

Fig. 5. Ground section representing implant and surrounding tissues. (a) Woven bone (dark stained areas, WB) is interposed between the implant surface (I) and the socket wall. (Straumann ITI standard implant). Levai Laczko staining. Original magnification × 5. (b) Detail of (a). Note the woven bone coronal to the marginal bone crest (Bc). Levai Laczko staining. Original magnification × 10. I, implant surface; PB, parent bone.

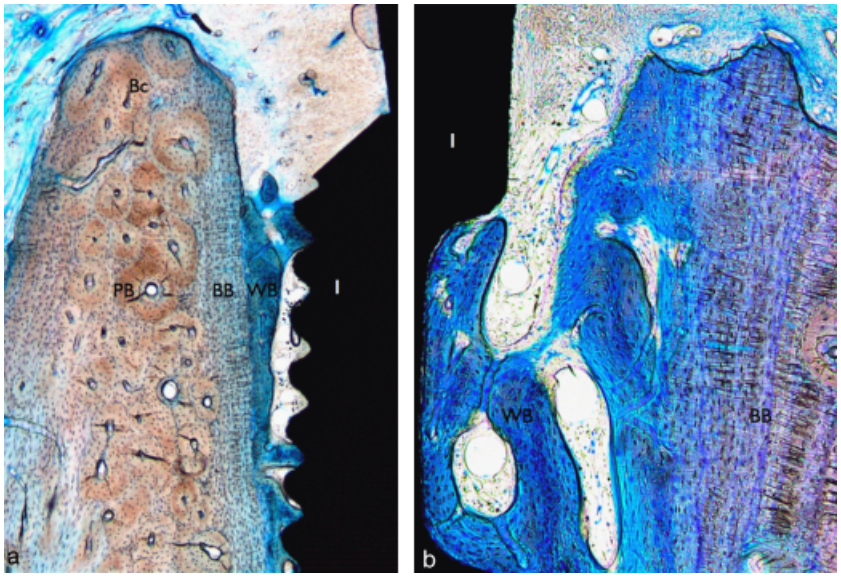

Fig. 6. Ground section representing implant and surrounding tissues. (a) Lingual bone crest (Bc) comprised of parent bone (PB), bundle bone (BB) and woven bone (WB). (I) Implant surface. Levai Laczko staining. Original magnification × 5 (Astra MicroThread® OsseoSpeed® implant). (b) Woven bone continuous with the bundle bone. Levai Laczko staining. Original magnification × 10. I, implant surface. PB, parent bone; WB, woven bone (Thommen SPI ELEMENT® implant).

of Thommen and Strauman implants were positioned coronal to the crest of bone. Measurement demonstrated 2.54 (1.39) and 2.95 (1.79) mm of bone loss for 3i and Straumann implants, respectively. Astra Tech and Thommen implants demonstrated a lower resorption of the buccal bone, averaging 2.06 (1.63) and 2.02 (1.27) mm, respectively. These differences, however, were not statistically significant (Table 2). The most coronal BIC (B) was identified at various positions apical to the implant shoulder (I–B distance). On the buccal side, it was located at approximately 3 mm, for 3i and Straumann implants and 2 mm for Astra Tech and Thommen. These differences, however, were not statistically significant. On the lingual side, differences were statistically significant only between Straumann and Astra Tech implants (Table 2).

The distance Bc–B is representative of the infra-bony component around the implant. At the buccal aspect almost no residual defect was present in all implants. At the lingual side, a residual gap was more common. In Thommen and Straumann implants, this defect averaged between 1 and 1.5 mm, while almost no defect was observed at Astra Tech and 3i implants. Still, these differences were not statistically significant.

New bone formation

Results from this outcome variable that expresses the percentage of new mineralized tissue fraction in a selected area (inside the thread) are shown in Table 3. Astra Tech implants showed the highest values of new bone formation, averaging 54.08% (21.45) of newly formed bone inside the thread 6 weeks after implant placement. The results for the other three systems were similar, averaging approximately 49% of new mineralized tissue inside the thread. The differences among the implant systems were not statistically significant.

Bone area

Results from this histomorphometric outcome variable that expresses the percentage of total mineralized tissue fraction inside the thread are shown in Table 3. This percentage was similar in the four-implant systems, with mean percentages of 77.68 (12.53), 71.60 (16.02), 61.60 (9.78) and 74.49 (13.74) for 3i, Astra Tech, Straumann and Thommen implants, respectively.

Table 1. Results from histometric measurements describing bone to implant contact (BIC) per dog

Dog	3i	Astra Tech	Straumann	Thommen
1	48.20	53.13	68.53	66.48
2	39.84	62.12	77.47	86.88
3	54.52	68.14	58.14	68.74
4	78.63	55.88	82.52	69.49
5	58.23	64.43	58.83	64.60
6	60.38	65.64	83.40	81.48
7	68.42	76.58	76.59	50.13
8	59.97	35.78	71.41	60.64
Total *N*	8	8	8	8
Mean	58.52	60.21	72.11	68.55
Minimum	39.84	35.78	58.14	50.13
Maximum	78.63	76.58	83.40	86.88
Standard deviation	11.82922	12.23288	9.77941	11.50059

Table 2. Results from mean (SD) histomorphometric measurements reporting the percentages of new bone area (NB) and total bone area (TB) in the thread.

Implant	% NB (SD)	% TB (SD)
3i	49.01 (19.48)	77.68 (12.53)
Astra Tech	54.08 (21.45)	71.60 (16.02)
Thommen	49.91 (12.83)	61.60 (9.78)
Straumann	49.49 (18.53)	74.49 (13.74)

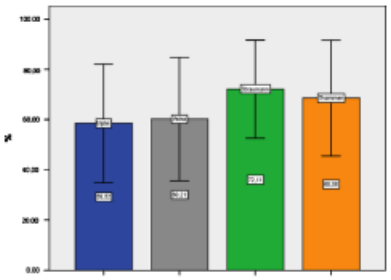

Fig. 7. Histograms depicting bone to implant contact (BIC) percentages.

Table 3. Results from mean (SD) histometric measurements (mm) reporting the distance between the various landmarks

Implant	I–B buccal	I–B lingual	I–Bc buccal	I–Bc lingual	Bc–B buccal	Bc–B lingual
3i	3.09 (1.52)	1.9 (0.39)	2.54 (1.39)	1.09 (0.48)	0.29 (0.39)	0.57 (0.87)
Astra	2 (0.48)	*0.75 (0.36)	2.06 (1.63)	0.68 (0.32)	−0.05 (1.54)	0.08 (0.45)
Thommen	1.98 (0.48)	1.61 (1.08)	2.02 (1.27)	0.72 (0.67)	0.09 (0.98)	1.13 (1.30)
Straumann	3.18 (1.46)	*2.53 (1.08)	2.95 (1.79)	0.75 (1.67)	0.46 (0.55)	1.50 (1.27)

*$p < 0.05$.

I, implant shoulder (for Straumann and Thommen implant: coronal limit of the treated surface); B, most coronal contact between the implant surface and bone; Bc, marginal portion of the bone crest.

Discussion

The main purpose of this study was to compare the healing of four different implant systems when placed experimentally using a specific surgical protocol (immediate placement in fresh extraction sockets). From the four-implant systems tested, Astra Tech, 3i and Thommen were cylindrical-shaped two-piece implant designs, although the latter presented a 1 mm machined collar. Straumann was a cylindrical-shaped one-piece design with a 1.8 mm machined collar.

We used the achieved percentage of bone to implant contact (BIC%) at 6 weeks as the main outcome variable. For Thommen and Straumann implants, this percentage was close to 70%, while for Astra and 3i the achieved mean percentages were 60.2% and 58.5%, respectively (Fig. 7). These differences, however, were not statistically significant. These results are consistent with those reported by Schultes & Gaggl (2001), who reported BIC values of 76% after a healing period of 8 months using the same surgical protocol. Similar results, with BIC values around 50% at 2 months and 54% at 4 months were also reported by Botticelli et al. (2006) in an experimental study in dogs.

The histomorphometric analysis also showed similar results for the four-implant systems studied. In the hard tissues, the percentage of newly formed bone within the thread amounted to approximately 50% and the total area of hard-tissue component around the implants filled between 61% and 77% of the thread area.

The alveolar ridge around the four types of implants showed marked resorption, with a mean bone loss of 2.5 mm observed at the buccal aspect of the crest, indicating that different implant surfaces and different geometries did not influence the process of bone remodelling that occurs in the socket after tooth extraction. These findings are in agreement with the observations reported by Araujo et al. (2005) in experimental beagle dog studies. These authors reported that the level of the buccal crest was located 2.6 ± 0.4 mm apical to the most coronal level of the sand-blasted and acid-etched, coated, surface implants. However, a recent similar experimental study in the beagle dog using the same surgical approach reported significant less vertical resorption of the buccal bone plate, with a mean bone loss of 0.63 (0.27) mm 8 weeks after the immediate placement of 3.25 mm diameter implants (Vignoletti et al. accepted for publication). Similar results were also reported in another experimental study in dogs, comparing flap *versus* flapless surgery when placing 3.3 mm diameter implants. At 3 months of healing, the vertical bone resorption at the buccal plate was 1.33 and 0.8 mm in the flapped and the flapless group, respectively (Blanco et al. 2008). These marked differences are probably dependent on different factors, such as the implant diameter, the width of the alveolar crest and the dimensions of the marginal gap, which highlights the importance of being cautious while using this surgical protocol.

In conclusion, this comparative animal experimental study has demonstrated that 6 weeks after immediate implant placement, different implant designs and implant surfaces do not significantly influence bone healing at fresh extraction sockets.

Acknowledgement

We highly appreciate Prof. Fernando Muñoz for his collaboration in the histological processing of this material.

References

Anneroth, G., Hedstrom, K. G., Kjellman, O., Kondell, P. A. & Nordenram, A. (1985) Endosseus titanium implants in extraction sockets. An experimental study in monkeys. *International Journal of Oral Surgery* **14**, 50–54.

Araujo, M. G., Sukekava, F., Wennstrom, J. L. & Lindhe, J. (2005) Ridge alterations following implant placement in fresh extraction sockets: an experimental study in the dog. *Journal of Clinical Periodontology* **32**, 645–652.

Barzilay, I., Graser, G. N., Iranpour, B. & Natiella, J. R. (1991) Immediate implantation of a pure titanium implant into an extraction socket: report of a pilot procedure. *International Journal of Oral & Maxillofacial Implants* **6**, 277–284.

Barzilay, I., Graser, G. N., Iranpour, B., Natiella, J. R. & Proskin, H. M. (1996a) Immediate implantation of pure titanium implants into extraction sockets of Macaca fascicularis. Part II: histologic observations. *International Journal of Oral & Maxillofacial Implants* **11**, 489–497.

Barzilay, I., Graser, G. N., Iranpour, B. & Proskin, H. M. (1996b) Immediate implantation of pure titanium implants into extraction sockets of Macaca fascicularis. Part I: clinical and radiographic assessment. *International Journal of Oral & Maxillofacial Implants* **11**, 299–310.

Blanco, J., Nunez, V., Aracil, L., Munoz, F. & Ramos, I. (2008) Ridge alterations following immediate implant placement in the dog: flap versus flapless surgery. *Journal of Clinical Periodontology* **35**, 640–648.

Botticelli, D., Persson, L. G., Lindhe, J. & Berglundh, T. (2006) Bone tissue formation adjacent to implants placed in fresh extraction sockets: an experimental study in dogs. *Clinical Oral Implant Research* **17**, 351–358.

Cornelini, R., Cangini, F., Covani, U. & Wilson, T. G. Jr. (2005) Immediate restoration of implants placed into fresh extraction sockets for single-tooth replacement: a prospective clinical study. *International Journal of Periodontics & Restorative Dentistry* **25**, 439–447.

Covani, U., Bortolaia, C., Barone, A. & Sbordone, L. (2004) Bucco-lingual crestal bone changes after immediate and delayed implant placement. *Journal of Periodontology* **75**, 1605–1612.

Covani, U., Marconcini, S., Galassini, G., Cornelini, R., Santini, S. & Barone, A. (2007) Connective tissue graft used as a biologic barrier to cover an immediate implant. *Journal of Periodontology* **78**, 1644–1649.

Donath, K. & Breuner, G. (1982) A method for the study of undecalcified bones and teeth with attached soft tissues. The Sage–Schliff (sawing and grinding) technique. *Journal of Oral Pathology* **11**, 318–326.

Ganeles, J. & Wismeijer, D. (2004) Early and immediately restored and loaded dental implants for single-tooth and partial-arch applications. *International Journal of Oral & Maxillofacial Implants* **19** (Suppl.), 92–102.

Karabuda, C., Sandalli, P., Yalcin, S., Steflik, D. E. & Parr, G. R. (1999) Histologic and histomorphometric comparison of immediately placed hydroxyapatite-coated and titanium plasma-sprayed implants: a pilot study in dogs. *International Journal of Oral & Maxillofacial Implants* **14**, 510–515.

Karnovsky, M. J. (1965) A formaldehyde–glutaraldehyde fixative of high osmolarity for use in electron microscopy. *Journal of Cell Biology* **27**, 137A–138A.

Schropp, L., Kostopoulos, L. & Wenzel, A. (2003) Bone healing following immediate versus delayed placement of titanium implants into extraction sockets: a prospective clinical study. *International Journal of Oral & Maxillofacial Implants* **18**, 189–199.

Schultes, G. & Gaggl, A. (2001) Histologic evaluation of immediate versus delayed placement of implants after tooth extraction. *Oral Surgery, Oral Medicine, Oral Pathology Oral Radiology, and Endodontics* **92**, 17–22.

Vignoletti, F., de Sanctis, M., Berglundh, T., Abrahamsson, I. & Sanz, M. Early healing of immediate implants into fresh extraction socket. An experimental study in the bagle dog. II. Ridge alterations (accepted for publication).

Vignoletti, F., Johansson, C., Albrektsson, T., de Sanctis, M., San Roman, F. & Sanz, M. (2009) Early healing of implants placed into fresh extraction sockets: an experimental study in the beagle dog. De novo bone formation. *Journal of Clinical Periodontology* **36**, 265–277.

Address:
F. *Vignoletti*
Facultad de Odontología
Plaza Ramon y Cajal s/n
Madrid
28040 Spain
E-mail: fabiovignoletti@mac.com

Clinical Relevance

Scientific rationale for the study: Immediate implant placement after tooth extraction is a common surgical protocol in clinical practice. Limited information is available, however, on the possible influence that different implant designs and surface modifications may have on the healing processes and on the final outcome of this surgical protocol. It is, therefore, relevant to study whether using different implants would influence the healing outcome when using this surgical approach.
Principal findings: The results from the histological outcomes failed to demonstrate significant differences among the implant systems studied after 6 weeks of healing. The histometric measurement of BIC did not reveal any statistically significant difference. A marked resorption of the buccal plate was observed independent of the implant system used.
Practical implications: The placement of a dental implant immediately upon tooth extraction results after healing in 2.5 mm of mean resorption of the buccal plate. This finding has clinical implications that should make the clinician aware of the limitations of this surgical protocol, mainly in areas of aesthetic concern.