

Ramón Lorenzo  
Virginia García  
Marco Orsini  
Conchita Martín  
Mariano Sanz

# Clinical efficacy of a xenogeneic collagen matrix in augmenting keratinized mucosa around implants: a randomized controlled prospective clinical trial

## Authors' affiliations:

Ramón Lorenzo, Graduate Periodontology, Faculty of Odontology, University Complutense of Madrid and Branemark Osseointegration Center, Madrid  
Virginia García, Marco Orsini, Conchita Martín, Mariano Sanz: Graduate Periodontology, Faculty of Odontology, University Complutense of Madrid

## Corresponding author:

Prof. Mariano Sanz  
Facultad de Odontología  
Universidad Complutense de Madrid  
Plaza Ramón y Cajal  
28040 Madrid  
Spain  
Tel.: +34913941901  
Fax: +34913941910  
e-mail: marianosanz@odon.ucm.es

**Key words:** collagen matrix, dental implants, keratinized tissue, oral mucosa

## Abstract

**Aim:** The aim of this controlled randomized clinical trial was to evaluate the efficacy of a xenogeneic collagen matrix (CM) to augment the keratinized tissue around implants supporting prosthetic restorations at 6 months when compared with the standard treatment, the connective tissue autograft, CTG).

**Materials and methods:** This randomized longitudinal parallel controlled clinical trial studied 24 patients with at least one location with minimal keratinized tissue ( $\leq 1$  mm).

**Main outcome measure:** The 6-month width of keratinized tissue. As secondary outcomes the esthetic outlook, the maintenance of peri-implant mucosal health and the patient morbidity were assessed pre-operatively and 1, 3, and 6 months post-operatively.

**Results:** At 6 months, Group CTG attained a mean width of keratinized tissue of 2.75 (1.5) mm, while the corresponding figure in Group CM was 2.8 (0.4) mm, the inter-group differences not being statistically significant. The surgical procedure in both groups did not alter significantly the mucosal health in the affected abutments. There was a similar esthetic result and significant increase in the vestibular depth in both groups as a result of the surgery. In the CM group it changed from 2.2 (3.3) to 5.1 (2.5) mm at 6 months. The patients treated with the CM referred less pain, needed less pain medication, and the surgical time was shorter, although these differences were not statistically significant when compared with the CTG group.

**Conclusions:** These results prove that this new CM was as effective and predictable as the CTG for attaining a band of keratinized tissue.

The question of whether or not a sufficient amount of keratinized tissue around natural teeth is necessary for long-term periodontal health is still controversial, although there is sufficient evidence to state that in the absence of inflammation, there is no minimum amount of keratinized gingiva to maintain periodontal attachment levels (Lang & L oe 1972; Dorfman et al. 1982; Wennstr om & Lindhe 1983; Kennedy et al. 1985). The presence of keratinized tissue is probably relevant, however, in specific clinical situations, such as around teeth, being abutments of fixed prosthetic restorations with subgingivally placed margins. In a 10-year prospective case series study (Valderhaug & Birkeland 1976) these sites lacking keratinized tissue demonstrated a significantly higher rate of gingival inflammation, attachment loss, and gingival recession. Similarly, in patients with

fixed partial prosthesis with natural teeth as abutments with minimal amount of keratinized tissue ( $\leq 1$  mm), the use of connective tissue grafts (CTGs) resulted in a significant gingival augmentation, which favored plaque control, reduced gingival inflammation, and attachment loss, when compared with equivalent non-grafted sites (Orsini et al. 2004). The possible influence of the width and thickness of the keratinized mucosa (KM) around implant-supported restorations, both on implant survival and on the stability of peri-implant tissues is also still controversial. A recent systematic review (Grusovin et al. 2008) reported that there is insufficient or even a lack of evidence regarding the possible influence of the width of keratinized tissue on the survival rate of dental implants, but in spite of this lack of clear evidence, three recent clinical studies have shown a positive

## Date:

Accepted 28 May 2011

## To cite this article:

Lorenzo R, Garc a V, Orsini M, Mart n C, Sanz M. Clinical efficacy of a xenogeneic collagen matrix in augmenting keratinized mucosa around implants: a randomized controlled prospective clinical trial.  
*Clin. Oral Impl. Res.* 00, 2011, 1–9.  
doi: 10.1111/j.1600-0501.2011.02260.x

correlation between lack or minimal amounts of KM and mucosal recession. In a 3-year retrospective study in 339 implants Chung et al. (2006) reported that the absence of adequate KM, especially in posterior implants, was associated with higher plaque accumulation and gingival inflammation, but not with more peri-implant bone loss. Similarly in a retrospective evaluation of 250 implants after 5–10 years in function, there was a significant negative correlation between Gingival Index (GI) and recession with the amount of KM (Artzi et al. 2006). A retrospective study that was specifically aimed to study the influence of the KM thickness and width around dental implants on both clinical and immunological parameters evaluated 53 implants after 1 year in function. The results showed that a narrow band of KM ( $\leq 1$  mm) was associated with significantly higher mucosal recession. Similarly, a thin mucosa ( $\leq 1$  mm) was also associated with significant recession (Zigdon & Machtei 2008). The importance of the KM around dental implants has been further emphasized by the results from an experimental study in monkeys reporting that ligated implants without KM accumulated more dental plaque and had significantly more recession and attachment loss than implants with KM (Warrer et al. 1995).

To overcome this problem, different authors have proposed diverse surgical techniques and materials to augment the soft tissues around teeth and dental implants. The surgical approach most frequently used is the apically repositioned flap plus the application of an autogenous graft (APF-AG) harvested from the palatal mucosa. The efficacy of these techniques has been recently evaluated in a systematic review (Thoma et al. 2009). From a total of 12 studies, the use of APF-AG resulted in a statistically significant weighted mean difference of 4.49 mm compared with no treatment. Allograft materials, such as the acellular dermal matrix graft (ADM, Alloderm®; Life Cell Corporation, The Woodlands, TX, USA) or the human fibroblast-derived dermal substitute (HF-DDS, Dermagrafts®; Advanced Tissue Sciences Inc., La Jolla, CA, USA) have also been utilized as an alternative to APF-AG, although the results reported in terms of increase in width of keratinized tissue were significantly inferior (Wei et al. 2002; McGuire et al. 2008).

Recently, a two-layer, xenogeneic collagen matrix (CM) has been investigated for the treatment of dehiscence defects around teeth (McGuire & Scheyer 2010) and for augmenting keratinized tissue around teeth and implants

supporting fixed prosthetic restorations (Sanz et al. 2009). Results from this randomized clinical trial demonstrated similar increase in the amount of keratinized tissue when the xenogenic soft tissue substitute was compared with autogenous CTGs (Sanz et al. 2009). There are, however, no clinical trials yet published, studying the use of this CM graft material to specifically enhance KM around implant-supported restorations. The aim of this parallel randomized clinical trial is to evaluate the efficacy of this xenogeneic CM to augment the band of KM around implants supporting prosthetic restorations at 6 months, when compared to the standard treatment, the free connective tissue auto-graft. Secondly the esthetic outcome and the patient's post-operative morbidity will also be assessed.

## Material and methods

### Patients

Patients wearing implant-supported prosthesis were selected from the maintenance programs of the Periodontal Postgraduate Clinic at the Faculty of Odontology in the University Complutense of Madrid and the Branemark Osseointegration Center in Madrid. After a screening examination consisting on full mouth examination with registration of probing pocket depths, bleeding scores (FMBS), and plaque scores (FMPS), 24 patients were enrolled for this study on the basis of fulfillment of these inclusion criteria:

- Being older than 18 years and being systemically healthy.
- Presenting at least one location with minimal or no keratinized tissue ( $\leq 1$  mm). The selected location must be an abutment of an implant-supported restoration.
- The patient should demonstrate a good plaque control (FMPS < 20%) and being able to comply with all procedures related to the study.

Patients were excluded if they were heavy smokers (more than 10 cigarettes/day), suffering any systemic disease that would negatively influence wound healing or known allergy to collagen.

Informed consent was obtained from all selected subjects. The Clinical Research Committee from the San Carlos Clinical Hospital in Madrid had previously approved this consent form and the study protocol.

### Sample size

The sample size was calculated using  $\alpha = 0.05$  and the power  $(1 - \beta) = 80\%$ . For

the variability ( $\sigma = SD$ ), the value of 0.9 mm (Sanz et al. 2009) was used considering the increase in width of the KM as the main outcome variable. The minimum clinically significant value ( $\delta$ ) considered was 2 mm. On the basis of these data, the number of patients required to be enrolled to conduct this study was calculated as 20 patients. However, considering the possibility of having a certain amount of dropout patients (20%), the total number of requested patients was 24.

### Experimental design

This study was designed as a randomized longitudinal parallel controlled clinical trial comparing the use of a xenogeneic CM (Mucograft®; Geistlich Pharma AG, Wolhusen, Switzerland) with the free CTG to augment the width of KM. The study protocol and clinical trial was authorized by the Spanish Ministry of Health and approved by the Ethical Committee of San Carlos Clinical Hospital in Madrid.

### Experimental product information

The CM (Mucograft®) is a class III medical device according to the Medical Device Directive 93/42 (EEC definitions: 1.1: long-term implant; 1.2: implantable; 8: resorbable and 17: porcine origin). Its structure consists of two functional layers: a cell occlusive layer consisting of collagen fibers in a compact arrangement and a thick porous layer. This porous layer provides a space that favors the formation of a blood clot and the ingrowth of tissue from adjacent sites (Fig. 1c). This xenogenic graft has been cleared by the EU and US Food and Drug Administration for regenerative therapy involving teeth and implants.

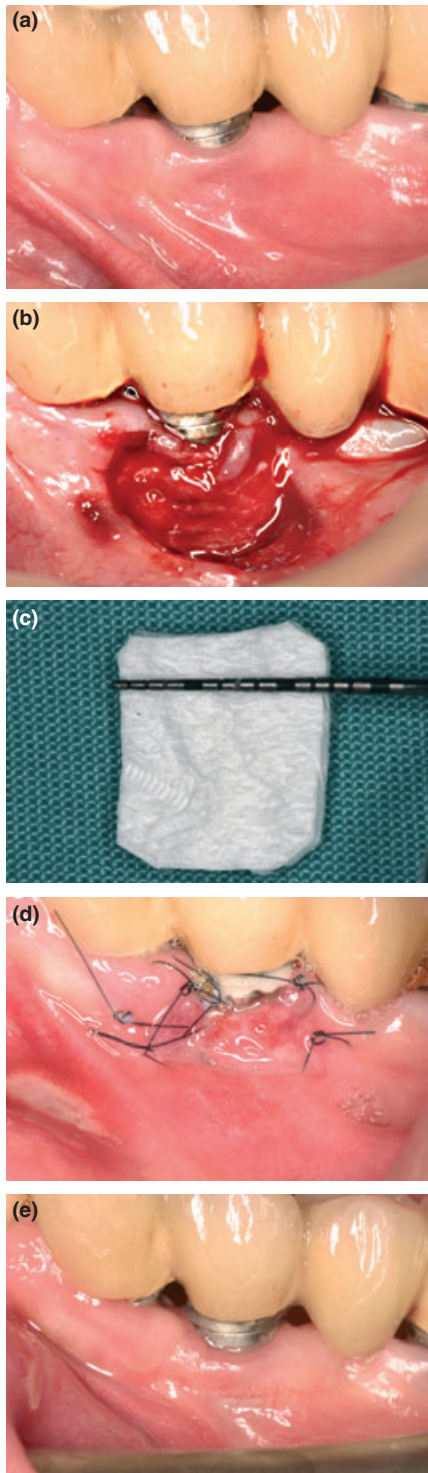
### Interventions

#### Investigator training

One examiner (V.G.) different from the surgical operators (R.L. and M.O.) was required to attend a training and calibration session aimed at: (i) instruction and calibration in the measurement techniques to be used; (ii) instruction in the compilation of the data collection sheets and (iii) preliminary data recording session.

### Treatment phase I: instruction of oral hygiene procedures

After having entered into the study, all patients received the following procedures by the same operator (V.G.) 4 weeks prior to the baseline visit:



**Fig. 1.** (a) Pre-surgical image from an experimental site. Note the minimal amount of keratinized tissue around an implant-supported restoration. (b) Split-thickness flap elevated to prepare the surgical bed for the Mucograft® in the experimental sites. Note the preservation of the minimal band of remaining keratinized tissue. (c) Experimental soft tissue substitute, a three-dimensional collagen tissue matrix (Mucograft®). (d) Healing of the collagen matrix at 10 days post-surgery. (e) Presence of a band of keratinized gingival/mucosa (3 mm) at 6 months in the experimental site treated with the collagen matrix.

- Supportive periodontal treatment consisting of oral hygiene instructions, a professional prophylaxis and if needed, scaling and root planning.
- A new toothbrush was given to each patient to assure proper oral hygiene according to the given instructions.

#### Outcome measurements

At the baseline visit, immediately before the surgical procedure, all subjects had the following clinical parameters being recorded (Figs 1a and 2a):

- The width of the KM at the implant abutment buccal site measured in mm from the mucosal margin to the mucogingival junction.
- Periodontal clinical outcome measurements at the implant location and adjacent teeth (GI, Plaque Index [PI], probing pocket depth [PPD], clinical attachment levels [CAL]).
- The depth of the vestibule at the implant location measured in mm from the mucosal margin to the reflection of the vestibule when the cheeks were retracted with a mirror.
- Clinical photographs of the surgical area to register soft tissue color characteristics.

All clinical parameters were recorded with a North Carolina University probe by the same-blinded examiner to the treatment (V.G.).

#### Treatment phase II: surgical interventions

After the data collection the patients underwent the assigned surgeries by two experienced periodontists (R.L. and M.O.). The surgical intervention began with the administration of the appropriate local anesthesia and consisted of the following steps:

- An intrasulcular incision was made and a mucosal partial thickness flap was raised. The recipient site was prepared by sharp dissection to create a periosteal bed free of any muscle attachment.
- The resulting flap was excised or sutured at the base of the newly created vestibule with 5-0 non-resorbable t-mattress braided nylon sutures (Figs 1b and 2b).
- The treatment allocation to the experimental and control groups was assigned by means of sealed envelopes containing a code derived from a randomized list, to receive either:

- Free CTG – control group (Fig. 2c).
- CM – test group (Fig. 1c).

- In the control group, once the size of the graft was predetermined using a tin foil stent prepared over the recipient site, a free CTG was harvested from the palate, following the classical procedure described by (Langer & Langer 1985). The CTG thickness varied depending on the patient's palate availability, ranging between 1 and 3 mm. The obtained CTG was then sutured in the recipient bed with 5-0 non-resorbable braided nylon interrupted single sutures.
- In the experimental group, the CM was trimmed to closely adjust to the recipient site and then sutured in place with 5-0 non-resorbable braided nylon interrupted single sutures.

The surgery time was recorded in both groups to the closest minute from the start of the first incision to the accomplishment of the last suture.

#### Post-treatment instructions

As post-operative instructions, patients were instructed to rinse twice daily with a chlorhexidine mouth rinse (0.12%) during 2 weeks. Anti-inflammatory medication (Ibuprofen 400 mg) was provided to the patients in blister packs each containing 12 units and patients were given instructions to take this medication in case of pain or swelling. The patients were prompted to record the dosage used in a customized form and return non-used blister packs at the next follow-up visit. Sutures were removed after 10 days, when clinical photographs were taken to document the healing process (Figs 1d and 2d). At this first post-operative visit, patients recorded their pain experience by pointing in a visual analog scale from 0 to 10 (being 0 no pain and 10 severe pain) and by filling a pain questionnaire.

#### Patient evaluation of the operative procedure

The next follow-up visits took place at 1, 3, and 6 months after the surgery. In these visits, clinical photographs were taken and the following clinical outcome measurements were recorded by the same operator (V.G.): width of the KM, PPD, CAL, GI, and PI (Figs 1e and 2e).

At the 1-month evaluation patients also recorded their pain evaluation as in the 10-day visit.

#### Outcome measurements

The primary endpoint of the study was to attain an adequate width of the KM. This outcome was evaluated pre-operatively (base-



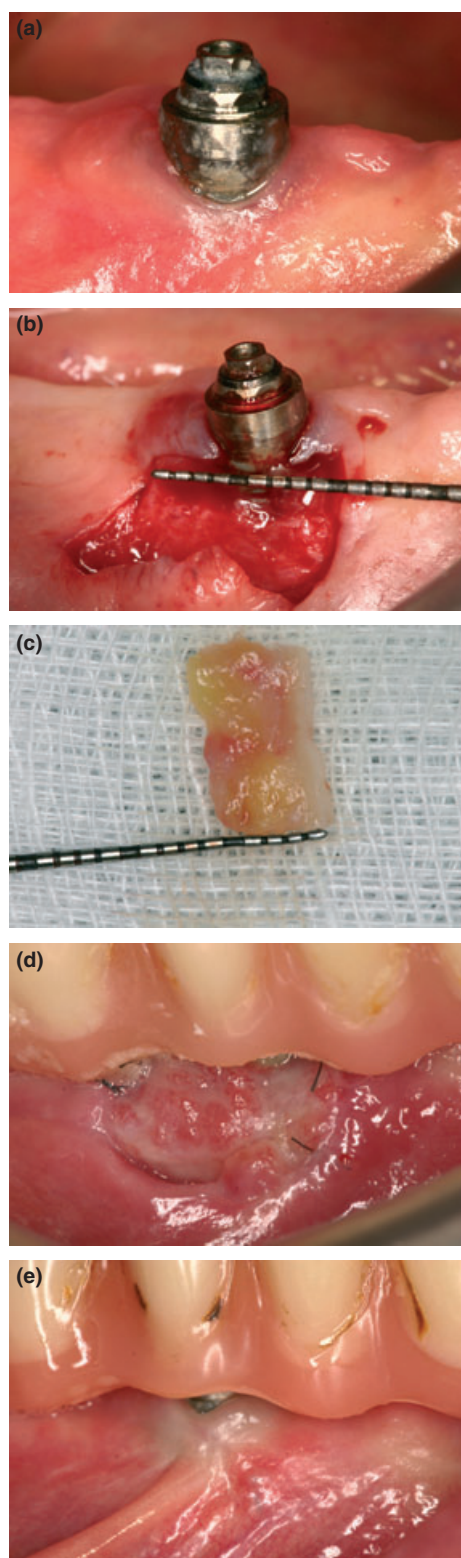


Fig. 2. (a) Pre-surgical image from a control site. Note the minimal amount of keratinized tissue around an implant-supported restoration. (b) Split-thickness flap elevated to prepare the surgical bed for the connective tissue auto-graft in the control sites. (c) Connective tissue graft harvested from the palatal mucosa. (d) Healing of the connective tissue graft at 10 days post-surgery. (e) Presence of a band of keratinized gingival/mucosa (3 mm) at 6 months in the control site treated with the connective tissue graft.

line) and at 1, 3, and 6 month after the treatment, by measuring the distance from the free mucosal margin to the mucogingival junction, using a North Carolina University probe, Figs 1e and 2e).

The secondary endpoints were the esthetic outcome, the maintenance of peri-implant health in the selected implant sites and the patient morbidity after the surgical procedure.

For assessing the peri-implant health status the following parameters were measured:

- GI, according to Loe and Silness.
- PI, according to Silness and Loe.
- PPD, measured in mm using a periodontal probe.
- CAL, measured in mm using a periodontal probe.

These peri-implant parameters were evaluated pre-operatively (baseline) and at 1, 3, and 6 months after the treatment.

The esthetic outcome was assessed from the standardized clinical photos taken of the augmented sites at each visit, by judging the color blending of the grafted site with the adjacent soft tissues through a qualitative questionnaire carried out by an independent examiner. No digital objective methods were used for this color evaluation.

The patient morbidity was assessed by measuring the amount of anti-inflammatory medication used by the patient and through the patient subjective evaluation assessed using a visual analog scale (0–10). The investigator recorded the presence of complications, additional treatments, and medication in connection to the surgical treatment, using a specific form and a questionnaire handed to the patients at the start of the post-operative visits.

#### Statistical and methodological methods

The study was monitored by an external agency in accordance with ISO 14155-1 and the obtained source data were verified for correctness and completeness before its statistical analysis.

The statistical analysis was per protocol. Descriptive statistics were generated for both the primary and secondary outcome measurements as means, SDs, 95% confidence intervals (CI), and medians with the corresponding lower and upper confidence limits. The normality of the distribution of these parameters was tested using the Kolmogorov–Smirnov test with the Dallal–Wilkinson–Lilliefors correction. The non-parametric Mann–Whitney test was used to compare the outcome variables at baseline

between control and test groups. For testing the treatment effect (inter-group comparisons), the time effect (intra-group comparisons), and the interaction between treatment and time we utilized the non-parametric method of Brunner–Langer. The changes between 6M and baseline were compared between groups (CM vs. CTG) for the primary and secondary outcome variables using the Wilcoxon's non-parametric test. The differences in pain at 10 days between both treatment groups were compared with the Mann–Whitney test. For all these comparisons we used a level of significance of 0.05.

#### Randomization and allocation concealment

In each subject, the selected site was randomly assigned to receive one of the two treatment regimens (CM or CTG). Treatment assignment was noted in the registration and treatment assignment form that was kept by the study monitor. Allocation concealment was performed using opaque sealed envelopes, sequentially numbered. The study monitor generated the allocation sequence by means of a computer-generated random permuted block (patient) and instructed a different subject (C.M., secondary investigator) to assign a sealed envelope containing the assigned treatment to each site. The randomization opaque envelope was opened immediately before the application of the graft material, once the recipient was prepared.

#### Blinding (masking)

The examiner (V.G.) was maintained blinded for the treatment.

#### Results

The study population consisted of 24 patients, 12 in the control group (CTG) and 12 in the experimental group (CM) recruited between September (2008) and February (2009). Fig. 3 depicts the flow chart of the study patients. All patients fulfilled the protocol, except two patients in the experimental group who due to personal reasons, increased significantly their smoking habit surpassing the threshold level defined in the protocol ( $\geq 10$  cigarettes/day) and hence, they were exited from the study. No patient in any of the groups suffered any significant complication. In the control group (CTG), one patient had a sports trauma and consequently, he was prescribed high doses of ibuprofen. This patient was excluded from the pain analysis, but was followed until the end of the study and the rest of the outcome

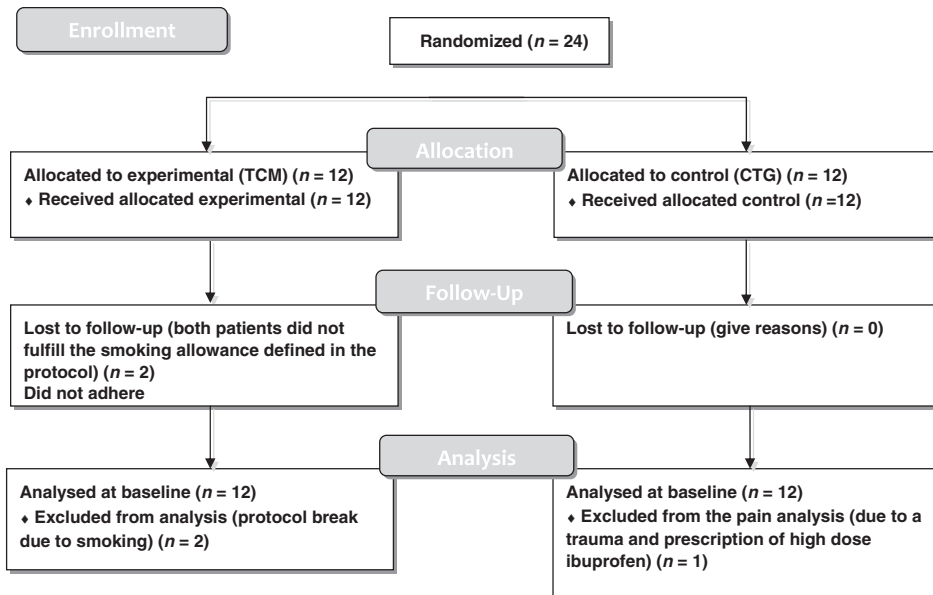


Fig. 3. Flow chart of the study patients.

measurements were included in the statistical analysis.

At baseline, both groups were well balanced with regard to patient characteristics and location of selected sites and therefore, no significant differences were shown in any of the clinical parameters assessed (Table 1). The selected population was mainly female with a mean age of 63 years. All the selected sites (except one) were mandibular sites, being evenly distributed between anterior/posterior sites in the control group, whereas there were more posterior sites (>70%) in the experimental group.

These differences, however, were not statistically significant.

The changes in the primary outcome variable (increase in KT) for all the study patients are shown in Table 2 (*P*-values are provided within the table). The mean width of KT at baseline in the control and experimental group was 0.42 (0.51) and 0.50 (0.52) mm, respectively. After the surgical procedure, there was a statistically significant increase in both groups (CTG and CM) at 30 days, being 3.17 (1.5) and 3.0 (0.7) mm, respectively. Differences between groups were not statistically significant. At 6 months, Group

CTG attained a mean width of keratinized tissue of 2.75 (1.5) mm, while the corresponding figure in Group CM was 2.8 (0.4) mm, being the inter-group differences not statistically significant. Between day 30 (1 month) and day 180 (6 months), there was more contraction in the control group (0.33), although differences with CM (0.2) were not significant. In the CM group the results attained at 30 days were mostly maintained at 180 days (Fig. 4). The group CM attained significant gains in keratinized tissue between baseline and 6 months (2.30 mm, *P* = 0.002). The corresponding value for the group CTG was 2.33 mm (*P* = 0.0005). Differences between groups were not significant (*P* = 0.58) (Fig. 4).

The surgical procedure in both groups did not alter significantly the periodontal parameters around the affected abutments (implants). Table 3 shows the changes in the GI, PPD, recession, and vestibular depth (VD). In Group CTG, the GI changed from 0.5 (0.6) at baseline to 0.3 (0.7) at 6 m. The corresponding figure in Group CM was 0.7 (0.9) and 0.2 (0.6), respectively. In both groups the inflammation in the marginal mucosa was reduced, although not significantly, when compared with baseline. Differences between groups were not significant. Similarly, the PD in the affected implant sites remained stable during the study in both groups. In Group CTG, the PD changed from 2.08 (0.9) at baseline to 2.08 (1.1) at 6 months. The corresponding figure in Group CM was 2.0 (0.7) and 1.6 (0.5), respectively. The changes in the position of the mucosal margin (recession) demonstrated a mean increase of about 0.5 mm of mucosal recession in both groups, but these differences were not statistically significant when compared with baseline or between the groups. In both groups the changes in VD resulted in a significant increase as a result of the surgery (*P* = 4.6661E-08) (Fig. 5). In Group CTG, the VD changed from 4.17 (3.3) at baseline to 6.00 (2.9) at 6 months (*P* = 0.0078). The corresponding figures in Group CM were 2.20 (3.2) at baseline and 5.1 (2.5) at 6 months (*P* = 0.0039). Differences between groups were not significant.

The evaluation of the clinical photographs provided similar results in esthetics and color blending with the adjacent tissues in both groups. The blind evaluators were not able to distinguish between both procedures in terms of color or esthetic outcome.

In spite of the lesser amount of pain and anti-inflammatory medication needed for the patients in the experimental group (CM)

Table 1. Comparison of demographic data between groups at baseline

	Baseline		<i>P</i> -value
	Group CTG	Group CM	
<b>Patients</b>			
Age: mean (SD)	63 (7.9)	62 (8.7)	0.827 (NS)
Gender: female/male	4/2	5/1	1 (NS)
<b>Sites</b>			
Anterior/posterior	6/6	4/8	0.680 (NS)
Maxilla/mandible	0/12	1/11	1 (NS)
<b>Clinical outcome measurements</b>			
<b>Keratinized tissue (mm)</b>			
Mean (SD)	0.42 (0.51)	0.5 (0.52)	0.731 (NS)
Median (CI)	0 (0, 1)	0.5 (0, 1)	
<b>Gingival Index</b>			
Mean (SD)	0.5 (0.67)	0.73 (0.9)	0.769 (NS)
Median (CI)	0.5 (0, 2)	0 (0, 1)	
<b>Probing pocket depth (mm)</b>			
Mean (SD)	2.08 (0.99)	2 (0.73)	0.951 (NS)
Median (CI)	2 (1, 3)	2 (1, 3)	
<b>Recession (mm)</b>			
Mean (SD)	0.67 (1.07)	1.08 (1.44)	0.545 (NS)
Median (CI)	0 (0, 2)	0.5 (0, 2)	

CTG, connective tissue graft; CM, collagen matrix. Clinical outcome measurements are expressed as mean (SD) and as median (upper and lower limits of confidence interval [CI]).

**Table 2.** Comparison of mm of keratinized tissue within each group and between groups

Patient no.	Keratinized tissue							
	Group CTG				Group CM			
	0 day	30 days	90 days	180 days	0 day	30 days	90 days	180 days
1	1	2	3	3	0	2	2	3
2	0	6	6	6	1			
3	0	5	3	4	1	3	3	3
4	1	4	4	4	0	4	3	3
5	0	2	2	2	0	2	2	3
6	0	1	1	1	1	3	3	3
7	1	3	2	3	1	3	3	3
8	0	3	2	1	1	3	3	3
9	0	3	2	2	0			
10	0	1	1	1	0	4	3	3
11	1	4	4	4	0	3	2	2
12	1	3	2	2	1	3	2	2
Mean	0.42	3.17	2.67	2.75	0.50	3.0	2.6	2.8
SD	0.51	1.53	1.44	1.55	0.52	0.67	0.52	0.42
95% CI	0.09, 0.74	2.2, 4.14	1.76, 3.58	1.77, 3.73	0.17, 0.83	2.34, 3.67	2.23, 2.97	2.50, 3.1
Median	0	3	2	2.5	0.5	3	3	3
95% CI	0, 1	2, 4	2, 4	1, 4	0, 1	2, 4	2, 3	2, 3
Statistics for Group		0.2151		Statistics for Time	80.6908		Statistics for Group × Time	0.089
P-value		0.643		P-value	0		P-value	0.938

CTG, connective tissue graft; CM, collagen matrix; CI, confidence interval. A Brunner–Langer model was applied to compare four time points (within-subject factor) and two groups (between-subjects factor). Values changed significantly (95%) over time but no treatment effect and of no interaction between treatment and time was found.

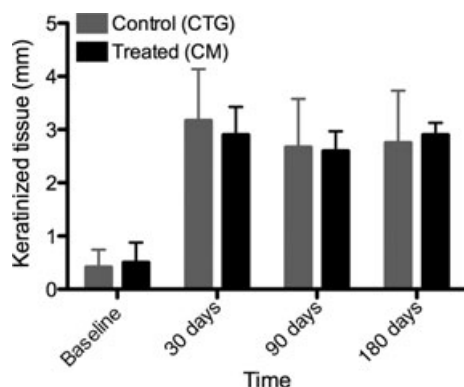


Fig. 4. Changes across time in the amount of keratinized tissue. Comparison between the collagen matrix (CM) and the connective tissue graft (CTG).

when compared with the control group (CTG), these differences were not statistically significant. Fig. 6 shows that in both groups, patients needed low dosages of ibuprofen during the immediate post-operative period, being <2000 mg in the CM group (about five 400 mg tablets as average), vs. <4000 mg in the CTG group (about eight 400 mg tablets as average). The amount of pain referred by the patient was measured through a visual analog scale, filled by each patient at the post-operative visits at 10 and 30 days. At 10 days patients in both groups reported very low pain (mean pain scores of <3). At 30 days there was no patient in the CM group that had any pain, while in the CTG group there were still patients

reporting minor pain (mean pain scores of <1).

The total surgery time spent in both surgical procedures was also different when both groups were compared. The CTG surgeries lasted a mean of 46.25 min, while the CM surgeries lasted a mean of 32.50 min. These differences were statistically significant ( $P = 0.0096$ ). Fig. 7 depicts these changes.

## Discussion

The present study was aimed to investigate the efficacy of a xenogenic CM to augment the band of KM around implants supporting prosthetic restorations at 6 months, when compared with the free connective tissue auto-graft. The results from this investigation confirm the previous published results using the same xenogenic material (Sanz et al. 2009) where a similar increase in width of keratinized tissue was attained when compared with an autogenous CTG. In both studies, the amount of new keratinized tissue attained with the xenogenic CM was similar, around 3 mm, and almost identical to what was attained with the autogenous CTG. These results can be considered modest, if compared with the results obtained using the same surgical technique by Orsini et al. (2004) that reported a mean increase of 5 mm 1 year post-surgically. These differences can be due to the different surgical sites used in both studies. In this investigation all except

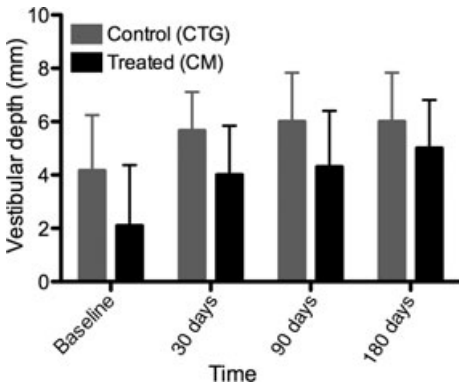
one were mandibular sites with shallow vestibules. In these mandibular sites the presence of high muscle attachments usually limit the amount of new keratinized tissue gained after the grafting procedures. Another possible cause limiting the amount of keratinized tissue may be the amount of shrinkage that occurred in this study to both the xenogenic and the CTGs. When using the traditional surgical technique of the APF plus the free gingival graft (FGG), Rateitschak, Egli & Fringeli (1979) evaluated its efficacy in a 4-year longitudinal study. The transplanted grafts demonstrated an average shrinkage of 25%, while the gingival margin remained stable during the observation period. Orsini et al. (2004) evaluated the 1-year results of a similar surgical technique, but using the CTG instead of the FGG. They reported 40% shrinkage, also with stable gingival margins after the 1-month evaluation. A recent systematic review (Thoma et al. 2009) has evaluated the efficacy of the different soft tissue augmentation techniques. When assessing the techniques aimed for increasing the width of keratinized tissue, 25 studies met the inclusion criteria, but only ten, however, were comparative studies evaluating the APF plus autogenous grafting as the standard of therapy. From these studies, four compared this surgical intervention vs. root planing or untreated controls; one vs. APF + vestibuloplasty and four vs. APF + allogeneic grafts. The overall weighted mean differences were statistically significant in favor of APF + autoge-



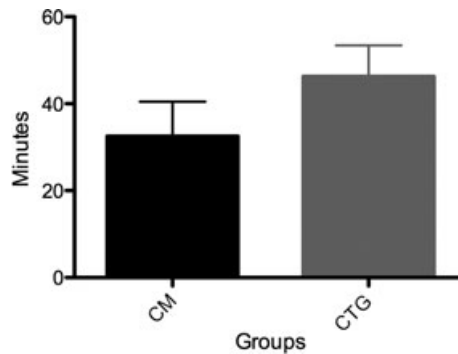
**Table 3. Descriptive statistics of secondary variables**

	Gingival Index		Probing depth (mm)		Recession (mm)		Vestibular depth (mm)	
	CTG	CM	CTG	CM	CTG	CM	CTG	CM
0 day								
Mean (SD)	0.5 (0.67)	0.73 (0.9)	2.08 (0.99)	2 (0.73)	0.67 (1.07)	1.08 (1.44)	4.17 (3.27)	2.20 (3.19)
Median (CI)	0 (0, 1)	0.5 (0, 2)	2 (1, 3)	2 (1, 3)	0 (0, 2)	1 (0, 3)	6 (1, 7)	1 (0, 5)
30 days								
Mean (SD)	0.17 (0.39)	0.5 (0.71)	2.17 (1.03)	1.7 (0.67)	1.08 (1.38)	1.4 (0.97)	5.67 (2.27)	4.1 (2.56)
Median (CI)	0 (0, 0)	0 (0, 0)	2 (1, 3)	2 (1, 2)	0 (0, 3)	1.5 (0, 2)	6 (3, 7)	4 (3, 6)
90 days								
Mean (SD)	0.25 (0.62)	0.3 (0.67)	2.42 (1.24)	1.7 (0.95)	1.17 (1.27)	1.4 (1.08)	6 (2.89)	4.6 (2.95)
Median (CI)	0 (0, 0)	0 (0, 0.25)	2.5 (1, 4)	1.5 (1, 2)	1 (0, 2)	1.5 (0, 3)	6 (3, 9)	4 (3, 7)
180 days								
Mean (SD)	0.33 (0.65)	0.2 (0.63)	2.08 (1.08)	1.6 (0.52)	1.17 (1.27)	1.5 (1.08)	6 (2.89)	5.1 (2.47)
Median (CI)	0 (0, 0.75)	0 (0, 0)	2 (1, 3)	2 (1, 2)	1 (0, 2)	1.5 (0, 3)	6 (3, 9)	4.5 (3, 7)
180 – 0 days								
Mean (SD)	-0.17 (0.94)	-0.6 (1.08)	0.00 (1.13)	-0.4 (1.07)	0.5 (1)	0.40 (1.51)	1.83 (1.59)	2.9 (2.23)
Median (CI)	0 (-1, 0)	0 (-2, 0)	0 (-1, 1)	0 (-2, 1)	0 (0, 1)	0 (0, 1)	2 (0, 3)	2.5 (1, 6)
Intra-group <i>P</i> -value	0.59	0.13	1.00	0.34	0.25	0.63	<b>0.0078</b>	<b>0.0039</b>
CTG vs. CM <i>P</i> -value		0.22		0.45		0.87		0.28

Statistically significant *P*-values (*P*<0.05) are in bold. Paired differences “180 days minus baseline” were calculated within each group (intra-group *P*-value) and compared between groups (CTG vs. CM *P*-value). CTG, connective tissue graft; CM, collagen matrix.



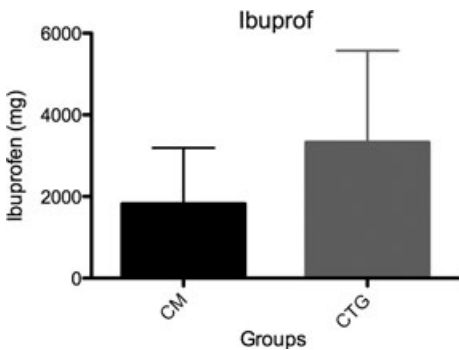
**Fig. 5.** Changes across time in the vestibular depth (VD). Comparison between the collagen matrix (CM) and the connective tissue graft (CTG).



**Fig. 7.** Differences in surgical time. Comparison between the collagen matrix (CM) and the connective tissue graft (CTG).

nous grafting, despite the large heterogeneity between the studies.

To overcome some of the shortcomings associated with the use of autogenous tissue, research activities have focused on the devel-



**Fig. 6.** Comparison between the collagen matrix (CM) and the connective tissue graft (CTG) with regard to the amount of anti-inflammatory medication taken (Ibuprofen®).

opment of alternative techniques and materials. In the late 1980s, allogeneic devices were introduced in mucogingival surgery predominantly as replacement for the classical FGGs. Among these allogeneic devices, the ADMG (Alloderm®; Life Cell Corporation) was used most frequently. The ADMG was originally developed for covering full-thickness burn wounds (Wainwright 1995). Intra-oral applications included procedures to increase the width of keratinized tissue, to cover recession defects, and to deepen the vestibular fornix (Aichelmann-Reidy et al. 2001; Wei et al. 2002; Harris 2003; Andrade et al. 2008). Several clinical studies have evaluated this allograft for its capability to increase the width of keratinized tissue around teeth and dental implants (Wei et al. 2002; Park 2006; Yan et al. 2006). Park (2006) in a prospective case series evaluating ADM to increase the width of KM around implants reported a mean increase of 2.2 mm at 6 months, with

a significant contraction of the grafted area (58%). Wei et al. (2002) compared the clinical efficacy of ADM with CTG in achieving increased keratinized tissue around implants. Although there was a statistically significant increase in both groups, this gain in keratinized tissue was significantly higher in the CTG when compared with ADM (5.5 mm vs. 2.5 mm) and also the contraction associated with this allograft was substantial (71%). More recently tissue-engineered products based on the use of cell substitutes, tissue-inducing substances (biologic mediators), and scaffolds of natural or synthetic origin have been developed and tested for this indication as substitutes for autogenous grafting. The HF-DDS (Dermagrafts; Advanced Tissue Sciences Inc.) and a human skin equivalent (BCT, Apligraf; Organogenesis, Canton, MA, USA) have been investigated in comparison with FGGs to increase the width of keratinized tissue (McGuire et al. 2008; Nevins 2010; Nevins et al. 2010). The amount of new keratinized tissue obtained with the HF-DDS was significantly inferior to what was obtained with the FGG (2.4 mm vs. 4.5 mm, respectively). With the human skin equivalent no clinical results have been yet reported.

Collagen devices from xenogenic origin have been extensively used in clinical dentistry, mostly as collagen barrier membranes in guided bone regeneration and guided tissue regeneration procedures (Hammerle & Jung 2003) and for the management of extraction sockets (Jung et al. 2004). In this investigation, the native collagen structure of the collagen device has been modified

to change the barrier properties of a collagen membrane to a porous CM with the purpose of serving as a scaffold for soft tissue integration. Its intended mechanism of action is by acting as a scaffold that allows the ingrowth and repopulation of fibroblasts, blood vessels, and epithelium from surrounding tissues, eventually being transformed into keratinized tissue. This behavior has been confirmed in experimental studies comparing two prototype CMs, one leading to the final commercial product (Mucograft®; Geistlich Pharma AG) used in this investigation. The histological evaluation at 6 months after implantation showed a safe integration of the experimental CMs into the surrounding tissue without any signs of inflammation and the attainment of a significant increase in thickness and width of the keratinized tissue (Jung et al. 2011). A similar xenogeneic collagen material, although with a different composition was also tested with the goal of promoting soft tissue augmentation when placed submerged under the flap in chronic ridge defects in dogs. The results showed a statistically significant gain when compared with the sham-operated control and similar volumetric gains when compared with the subepithelial connective tissue (Thoma et al. 2010).

Also this soft tissue substitute xenogeneic material has been recently tested clinically in humans. In a controlled prospective clinical trial evaluating this CM for augmenting the band of keratinized tissue around prosthetic abutments, it rendered similar results when compared with the gold standard (subepithelial CTGs) (Sanz et al. 2009). Its use in large mucosal defects has also reported good clinical outcomes (Herford et al. 2010).

In this study the application of the CM provided at 30 days an augmentation in keratinized tissue of 3.0 (0.7) mm, which is comparable with the similar gains attained with the control treatment, the free CTG (3.08 (1.5)). It is noticeable, however, that the application of the CM demonstrated more consistent results as shown by the differ-

ences in the standard deviation obtained (0.7 vs. 1.5). These results were almost identical to the previous clinical trial carried out by our research group using the same study material, also for the same clinical indication, although combining sites with teeth and implants as prosthetic abutments (Sanz et al. 2009). In this study the results were a gain in keratinized tissue of 2.8 (1.0) mm, almost identical to the 2.9 (0.7) mm obtained in this investigation. Also similar to the previous study, the patients treated with the CM reported lesser pain and need of post-operative anti-inflammatory medication when compared with the control group (CTG), although in this investigation these differences were not statistically significant. The differences between both studies are not due to the experimental group since in the patients treated with the CM the amount of pain was very low (visual analogue scale pain scores lower than 2) and the amount of needed medication was also minor (<2000 mg). The lack of statistical difference is due to the lesser pain and need of medication reported in the group treated with the autograft, which may be due to the patient profile, since in this investigation many patients were edentulous, which may account for the reduced pain in the donor site.

When these CMs have been used in the treatment of localized gingival recessions (McGuire & Scheyer 2010), they have also rendered good results ( $\geq 88\%$  root coverage), although slightly inferior to the use of autogenous CTGs (99%). In the present study, we have corroborated these previous results demonstrating a consistent creation of a stable band of keratinized tissue and deepened vestibule in sites with minimal or absent KM around dental implants. These results apply specifically to implants placed in the mandible, since the vast majority of patients treated in this investigation had mandibular implants. The width of this new KM and the depth of the vestibule was of similar dimensions as the gold standard treatment (the CTG from the palate) (2.8 mm vs. 2.75 mm,

respectively), although the use of the CM provided more predictable results (standard deviations at 6 m of 0.42 mm vs. 1.54 mm, respectively).

The integration of both graft materials and the esthetic results were excellent in both groups, without any soft tissue complications. The surgical time employed was shorter in the CM group, when compared with the CTG (32.5 min vs. 46.2 min, respectively), although these differences were not statistically significant.

In spite of the scarcity of information concerning the importance of the KM around dental implants and its effect on the peri-implant tissue health, clinical studies have confirmed that the lack of KM around implants correlated with plaque accumulation and soft tissue inflammation (Chung et al. 2006). Moreover, recent studies have shown a positive correlation between lack or presence of minimal amounts of KM and mucosa recession (Artzi et al. 2006; Chung et al. 2006; Zigdon & Machtei 2008), although a direct relationship with bone loss around implants or reduced implant survival rates has not been demonstrated (Grusovin et al. 2008).

In conclusion, the results of this study prove that the use of this xenogeneic CM, when used as a soft tissue substitute aiming to increase the width of KM around dental implants in the mandible was as effective and predictable as the connective tissue auto-graft.

**Acknowledgements:** The study has been supported by a research grant from Geistlich Pharma. The authors wish to acknowledge the diligent support regarding study monitoring and data management provided by Wolfgang Kleimeier and Lorenz Uebersax from Geistlich Pharma, and the statistical advice provided by Dr Ulrich Kreuter and Dr Michael Mayer (Consult AG Bern).

## References

- Aichelmann-Reidy, M.E., Yukna, R.A., Evans, G.H., Nasr, H.F. & Mayer, E.T. (2001) Clinical evaluation of acellular allograft dermis for the treatment of human gingival recession. *Journal of Periodontology* 72: 998–1005.
- Andrade, P.F., Felipe, M.E., Novaes, A.B. Jr., Souza, S.L., Taba, M. Jr., Palioto, D.B. & Grisi, M.F. (2008) Comparison between two surgical techniques for root coverage with an acellular dermal matrix graft. *Journal of Clinical Periodontology* 35: 263–269.
- Artzi, Z., Carmeli, G. & Kozlovsky, A. (2006) A distinguishable observation between survival and success rate outcome of hydroxyapatite-coated implants in 5–10 years in function. *Clinical Oral Implants Research* 17: 85–93.
- Chung, D.M., Oh, T.J., Shotwell, J.L., Misch, C.E. & Wang, H.L. (2006) Significance of keratinized mucosa in maintenance of dental implants with different surfaces. *Journal of Periodontology* 77: 1410–1420.
- Dorfman, H.S., Kennedy, J.E. & Bird, W.C. (1982) Longitudinal evaluation of free autogenous gingival grafts. A four year report. *Journal of Periodontology* 53: 349–352.
- Grusovin, M.G., Coulthard, P., Worthington, H.V. & Esposito, M. (2008) Maintaining and recovering



- soft tissue health around dental implants: a Cochrane systematic review of randomised controlled clinical trials. *European Journal of Oral Implantology* **1**: 11–22.
- Hammerle, C.H. & Jung, R.E. (2003) Bone augmentation by means of barrier membranes. *Periodontology* **2000**: 36–53.
- Harris, R.J. (2003) Soft tissue ridge augmentation with an acellular dermal matrix. *International Journal of Periodontics & Restorative Dentistry* **23**: 87–92.
- Herford, A.S., Akin, L., Cicciu, M., Maiorana, C. & Boyne, P.J. (2010) Use of a porcine collagen matrix as an alternative to autogenous tissue for grafting oral soft tissue defects. *Journal of Oral Maxillofacial Surgery* **68**: 1463–1470.
- Jung, R.E., Hurzeler, M.B., Thoma, D.S., Khraisat, A. & Hammerle, C.H. (2011) Local tolerance and efficiency of two prototype collagen matrices to increase the width of keratinized tissue. *Journal of Clinical Periodontology* **38**: 173–179.
- Jung, R.E., Siegenthaler, D.W. & Hammerle, C.H. (2004) Postextraction tissue management: a soft tissue punch technique. *International Journal of Periodontics & Restorative Dentistry* **24**: 545–553.
- Kennedy, J.E., Bird, W.C., Palcanis, K.G. & Dorfman, H.S. (1985) A longitudinal evaluation of varying widths of attached gingiva. *Journal of Clinical Periodontology* **12**: 667–675.
- Lang, N.P. & Löe, H. (1972) The relationship between the width of keratinized gingiva and gingival health. *Journal of Periodontology* **43**: 623–627.
- Langer, B. & Langer, L. (1985) Subepithelial connective tissue graft technique for root coverage. *Journal of Periodontology* **56**: 715–720.
- McGuire, M.K. & Scheyer, E.T. (2010) Xenogenic collagen matrix with coronally advanced flap compared to connective tissue with coronally advanced flap for the treatment of dehiscence-type recession defects. *Journal of Periodontology* **81**: 1108–1117.
- McGuire, M.K., Scheyer, E.T., Nunn, M.E. & Lavin, P.T. (2008) A pilot study to evaluate a tissue-engineered bilayered cell therapy as an alternative to tissue from the palate. *Journal of Periodontology* **79**: 1847–1856.
- Nevins, M.L. (2010) Tissue-engineered bilayered cell therapy for the treatment of oral mucosal defects: a case series. *The International Journal of Periodontics & Restorative Dentistry* **30**: 31–39.
- Nevins, M., Nevins, M.L., Camelo, M., Camelo, J. M., Schupbach, P. & Kim, D.M. (2010) The clinical efficacy of dynamatrix extracellular membrane in augmenting keratinized tissue. *The International Journal of Periodontics & Restorative Dentistry* **30**: 151–161.
- Orsini, M., Orsini, G., Benlloch, D., Aranda, J.J., Lazaro, P. & Sanz, M. (2004) Esthetic and dimensional evaluation of free connective tissue grafts in prosthetically treated patients: a 1-year clinical study. *Journal of Periodontology* **75**: 470–477.
- Park, J.B. (2006) Increasing the width of keratinized mucosa around endosseous implant using acellular dermal matrix allograft. *Implant Dentistry* **15**: 275–281.
- Rateitschak, K.H., Egli, U. & Fringeli, G. (1979) Recession: a 4-year longitudinal study after free gingival grafts. *Journal of Clinical Periodontology* **6**: 158–164.
- Sanz, M., Lorenzo, R., Aranda, J., Martin, C. & Orsini, M. (2009) Clinical evaluation of a new collagen matrix (mucograft prototype) to enhance the width of keratinized tissue in patients with fixed prosthetic restorations: a randomized prospective clinical trial. *Journal of Clinical Periodontology* **36**: 868–876.
- Thoma, D.S., Benić, G.I., Zwahlen, M., Hämmerle, C.H.F. & Jung, R.E. (2009) A systematic review assessing soft tissue augmentation techniques. *Clinical Oral Implants Research* **20**(Suppl. 4): 146–165.
- Thoma, D.S., Jung, R.E., Schneider, D., Cochran, D. L., Ender, A., Jones, A.A., Grolach, C., Uebersax, L., Graf-Hausner, U. & Hammerle, C.H. (2010) Soft tissue volume augmentation by the use of collagen-based matrices: a volumetric analysis. *Journal of Clinical Periodontology* **37**: 659–666.
- Valderhaug, J. & Birkeland, J.M. (1976) Periodontal conditions in patients 5 years following insertion of fixed prostheses. Pocket depth and loss of attachment. *Journal of Oral Rehabilitation* **3**: 237–243.
- Wainwright, D.J. (1995) Use of an acellular allograft dermal matrix (alloderm) in the management of full-thickness burns. *Burns* **21**: 243–248.
- Warrar, K., Buser, D., Lang, N.P. & Karring, T. (1995) Plaque-induced peri-implantitis in the presence or absence of keratinized mucosa. An experimental study in monkeys. *Clinical Oral Implants Research* **6**: 131–138.
- Wei, P.C., Laurell, L., Lingen, M.W. & Geivelis, M. (2002) Acellular dermal matrix allografts to achieve increased attached gingiva. Part 2. A histological comparative study. *Journal of Periodontology* **73**: 257–265.
- Wennström, J. & Lindhe, J. (1983) Role of attached gingiva for maintenance of periodontal health. Healing following excisional and grafting procedures in dogs. *Journal of Clinical Periodontology* **10**: 206–221.
- Yan, J.J., Tsai, A.Y., Wong, M.Y. & Hou, L.T. (2006) Comparison of acellular dermal graft and palatal autograft in the reconstruction of keratinized gingiva around dental implants: a case report. *The International journal of periodontics & restorative dentistry* **26**: 287–292.
- Zigdon, H. & Machtei, E.E. (2008) The dimensions of keratinized mucosa around implants affect clinical and immunological parameters. *Clinical Oral Implants Research* **19**: 387–392.